Special Review

Hematologic Changes in Dengue Hemorrhagic Fever+

Tanomsri Srichaikul

Vichaiyut Medical Center, Bangkok, Thailand

Introduction: The first epidemic of dengue hemorrhagic fever (DHF) occurred in Philippine and Thailand around 1952 and 1954.[1] The clinical manifestations almost always presented with high fever, shock, severe bleeding with multiorgan failure and death. At that time, pathogenesis and pathophysiology including the knowledge of dengue virus was not known. Many studies were performed leading to the better understanding on the pathogenesis and pathophysiology including the knowledge of dengue virus (DV).[1,2] This brought into the better management and decrease of mortality rate to 1-2%.[3-5] During the last 50 years the natural history of DHF has changed a great deal with the tremendously progression of new knowledge. Endothelial cell derangement become to be an important factor. It played a big role in the occurrence of plasma leakage leading to shock, release of tissue factor resulting in DIC and increase platelet aggregation and then the formation of platelet fibrin thrombi.[6-10] Furthermore, platelet dysfunction caused both bleeding and thrombosis.[11] All of these event caused ischemia of the vital end organs. Recently, increased incidence of adult DHF along with high mortality rate became to be an important problem.[12-16] Immunopathogenesis played an important role in the occurrence of the unusual manifestations in DHF such as hemophagocytic syndrome (HPCS) and related disorders.[17-18] With better understanding, effective treatment by immunomodulator such as high dose corticosteroid and intravenous immunoglobulin G were given to save life of the patients.[19-27] The key role for successful therapy was early diagnosis and effective treatment of hematophagocytic syndrome.

The three topic discuss below included bone marrow suppression, DIC and hemophagocytic syndrome are important. These should lead to the better understanding on the natural history of Dengue infection, which has changed a great deal during the lest 50 years. This knowledge will bring into the early diagnosis and most effective treatment to decrease the high fatality of DHF at the present time.

1. Bone Marrow Suppression in DHF

The hematopoietic suppression is a well known phenomenon occurred during dengue virus infection. The degree of this change was similar in both dengue and dengue hemorrhagic fever. The suppression of hematopoiesis began around 4-5 days after the innoculation of virus from the bites of an infected mosquito. This suppression lasted approximately 10 days and ended in the acute febrile phase approximately 2-3 days before shock or subsidence of fever. (Fig. 1) From various studies[28-30] the bone marrow of patients with DHF at the early phase of illness showed markedly

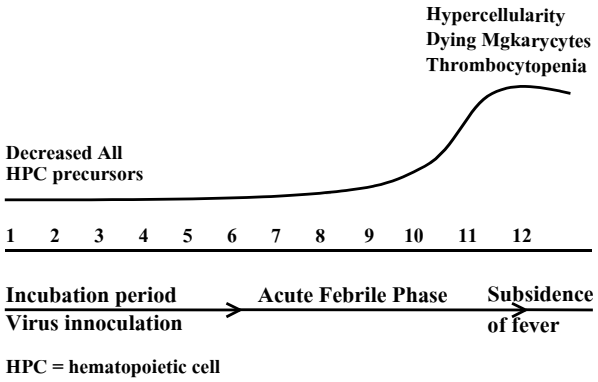

Fig. 1 Bone marrow changes in dengue infection

+ Present at International Congress of Dengue Infection, Oct 22, 2013 Bangkok, THAILAND

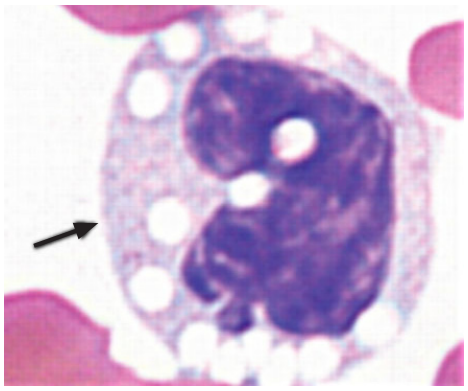

Fig. 2 Megakaryocyte showing negleected nuclei and cytoplasmic vacuolization

hypocellularity accompanying with decreased all the hematopoietic cell precursors namely megakaryocytes, erythroid and myeloid precursors. In vitro culture, the colony forming units granulocyte and macrophage (CFU-GM) were markedly decreased or almost absent. The colony size were also smaller or appeared as a cluster of cells. Following the hematopoietic suppression, the recovery of hematopoiesis occurred few days before shock or subsidence of fever. The bone marrow appeared hypercellular, accompanied by increase in number of megakaryocytes, erythroid and myeloid precursors. Despite the increase in normal number of megakaryocytes, these cells showed sign of degeneration as manifested by nuclear fragmentation and/or cytoplasmic vacuolization. (Fig. 2)[29-30,32] The hemophagocytosis of young and mature erythroid and myeloid cells including lymphocytes and platelets were also observed.[31-35]

Pathogenesis

The pathogenesis of bone marrow suppression in dengue hemorrhagic fever (DHF) involved three main factors. These were the direct injury of dengue virus infection and replication of the hematopoietic cell progenitors; the infection and replication of dengue virus in the stromal cells and the changes of marrow regulators.

The direct injury of dengue virus to the hematopoietic stem cells was demonstrated by Nakoa et al in 1989.[36] He showed that DV4 could replicate in normal bone marrow mononuclear cells. The replication of the virus caused inhibition on the proliferation of both burst forming unit erythroid colonies (BFU-E) and colony forming unit granulocyte - macrophages (CFU-GM). Later on, Murgur et al in 1997[37] demonstrated in vitro that DV3 could infect the cord blood mononuclear cell. This infection caused suppression of progenitor cell growth in cultures. The degree of hematopoietic suppression was correlated with the clinical spectrum of dengue infection. The most severe suppression was observed in dengue shock syndrome, followed by dengue hemorrhagic fever and dengue fever respectively.

The injury of dengue virus on the stromal bone marrow cells was observed by La Russa et al.[38-39] He demonstrated that the infection of the DV2 to the stromal cells caused inhibition on the growth of hematopoietic stem cells in the culture. From various studies in vitro[40-44] during the infection of DV to the stromal cells, many cytokines were released into the supernatant in culture. These cytokines were macrophage inflammatory protein-1 alpha (MIP-1 α), IL6 and IL8.[40] All of these cytokines inhibited on the growth of hematopoietic stem cells. Simultaneously, there was the decrease in stem cell factor leading to the decrease in supporting the growth of hematopoietic stem cells in culture. Recently, many investigators[45-51], showed that many cytokines which could suppress hematopoiesis were released into the circulation during the early acute febrile phase of dengue infection. These cytokines included tumor necrosis factor (INF α), interleukins (IL-6, IL-8) and interferons (INF α and INF γ). There was close correlation between the levels of these cytokines to the clinical severity of dengue infection. The duration of the bone marrow suppression was also corresponding with the increased level of these cytokines in the blood.

In summary, pathogenesis of bone marrow suppression in dengue and dengue hemorrhagic

fever involved three major mechanisms. These were the direct infection of dengue virus in to the hematopoietic stem cells and stromal cells of the bone marrow, accompanied by the release of various hematodepressive cytokines during the dengue virus infection. All of these factors caused hematopoietic suppression, resulting in granulocytopenia and thrombocytopenia. The hematopoietic suppression occurred transiently and recovered rapidly at the late acute febrile period. Following this recovery the number of neutrophils and platelets were furtherly decreased until the day of shock or subcidence of fever and then gradually returned to normal within 2 days at the convalescent period of the disease.[52]

DIC, Coagulation and Fibrinolysis, Thrombocytopenia and Platelet Dysfunction

At present, DIC is well known phenomena in DHF.[53-54] The first outbreak of DHF with DIC was observed in Philippine in 1953-1954[55] and then in Thailand in 1955 (personal experience). At that time little knowledge was known about phagenesis and pathophysiology of DHF including the causative virus. The classicle manifestations were the combination of intractable shock, severe bleeding and multiorgan failure, and the post mortem findings showed disseminated fibrin thrombi in many vital organs. The challenging question arised. Did the DIC occurred following prolong shock only or did it also occurred in the non-shock stage? This challenging questions stimulated us to find out for the answer. From our study in 1977[56] we demonstrated that mild DIC did already occurred in 56% of non-shock patients but it had no clinical significance. However, DIC was found in 82% of the shock group. Without adequate treatment for prevention of shock in order to get rid of the vicious cycle between shock and DIC, the patients would go into severe bleeding, intractable shock and multiorgan failure. In DHF with mild bleeding and intractable shock. DIC as an intermediary process inducing intractable shock should be suspected. In this situation small dose of heparin should be helpful.[54] In severe bleeding from DIC, Novo-7 a potent local hemostatic drug should be given.[57] On the other hand, exchange transfusion could be very helpful because it could removed all the thromboplastic substances and cytokines from the circulation. The replacement of blood component included pack red cells, cryoprecipitate, fresh frozen plasma and platelets which was given after exchange transfusion would stop bleeding. Finally, the correlation between activation of coagulation and fibrinolysis with the severity of DHF, DSS was found.[58-59] DIC and secondary fibrinolysis were found in majority of the cases but the degree of abnormality was more in DSS patients.[59] Bleeding was common manifestations in DHF. The severity of bleeding correlated well with the severity of the disease : DHF and DSS. Pathogenesis of bleeding could be explained on the basis of the interaction of vasculopathy, platelet abnormality both thrombocytopenia and platelet dysfunction, DIC and fibrinolysis.[60,61] Thrombocytopenia the most constant findings usually occurred in 2-3 days before shock or subcidence of fever. In the non-shock group, platelet nadir count was around 50,000 whereas in shock group it was less than 50,000.[52] The mechanism of thrombocytopenia in acute phase of DHF was mainly due to peripheral destruction.[62] Many line of evidences indicated that immune mechanism played a major role on the pathogenesis of thrombocytopenia.[63-66]

The role of corticosteroid to increase platelets during convalescence period in non-shock group were study. The result failed to demonstrate the benefit of corticosteroid.[67] Recently, the work of Srichaikul and her group[68] showed that corticosteroid had no role in increasing platelets in non-shock patients during the convalescent period. However, it suppressed fever and shortening the days of admission when given full dose at acute phase of DHF.

Hemophagocytic Syndrome and Related Disorders

The first report of hemophagocytic syndrome in DHF was in 2007.[19] The patient was 46 year old female, who presented with multiorgan failure at the recovery phase. She survived by receiving high dose corticosteroid and IVIg therapy.

Hemophagocytic Syndrome (HPCS) is characterized by four major manifestations. These were high fever, progressive cytopenia, multiorgan failure with initially present as hepatic failure, and finally the demonstration of hemophagocytosis in the bone marrow and other reticuloendothelial organs. This syndrome occurred mainly in immunocompromised host, in both children and adult but more in the adult. Two major disorders could cause HPCS. These were lymphoid malignancy and others and non-malignant disorders mostly from infections such as Ebstein Bar virus (EBV), DHF and others, bacteria protozoal and fungus, drugs, toxin and immune diseases such as SLE and rheumatoid arthritis. The prognosis of HPCS in virus infection was poor and needed early treatment by high dose corticosteroid and high dose intravenous immunoglobulin G to save life of the patients.[19-26]

Pathogenesis of HPCS[19-20,26-28] involved two major systems : T lymphocytes and macrophage. These two cell working synchronisely by stimulating many cytokines namely interleukins, interferon α and γ and tumour necrosis factor. The cytokines caused injury of vascular endothelial cells leading to clot formation, ischemia, multiorgan failure and bleeding. On the other hand the activated macrophage induced phagocytosis, in combination with activation of fas-ligend gene leading to apoptosis inturne resulting in more severe cytopenia. These unpleasant events resulted to secondary infection, shock, multiorgan failure and death. (Fig 3)

Our recent retrospective analysis of 157 DHF patients during 2008-2010[21] showed that 7 patients had severe complicated immune disorders. These were 4 HPCS and 3 related disorders. The clinical manifestation of these 7 cases were shock accompanied by ARDS in 3 cases, cardiomyopathy consisted of cardiomegaly in 4 and myocarditis in 1 cases. CNS involvement namely convulsion in 1 case, semiconscious in 1 case, cerebral hemorrhage in 1 case, gastrointestinal involvement namely nausea

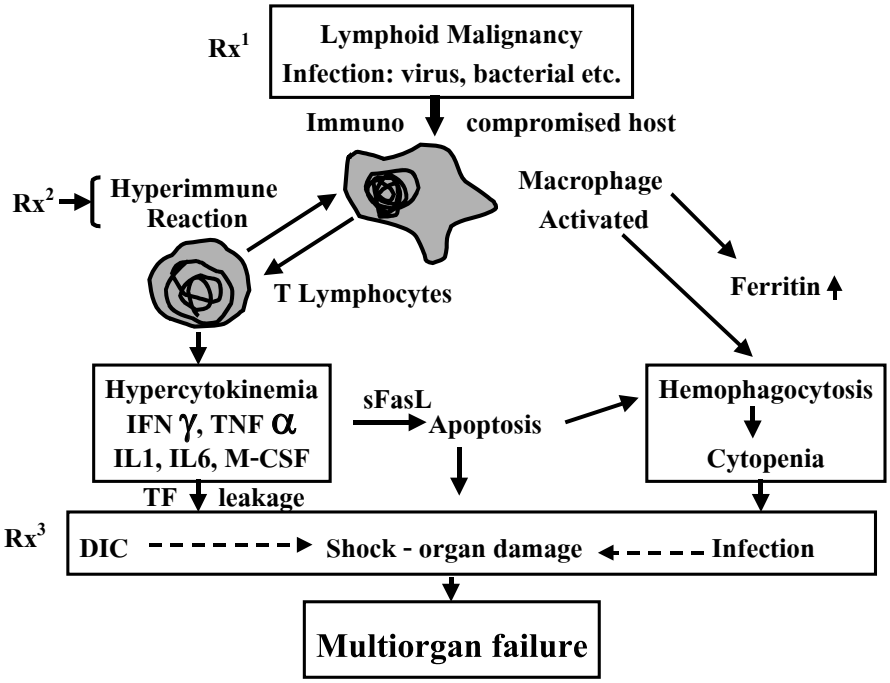

Fig. 3 Pathoghysiology of Hemophagocytic Syndrome

vomiting lose of appetite in 1 case, severe abdominal pain in 2 cases, severe gastrointestinal bleeding in 3 cases, severe hepatitis as manifested by jaundice, rising of liver enzyme >500 unit in 3 cases and acute renal failure : azothemia in 1 case, require hemodialysis in 1 case and required blood transfusion in 3 cases. Hematologic abnormalities consisted of acute anemia in 4 cases, initial leukocytosis in 2 cases, severe thrombocytopenia in 3 cases and DIC in 3 cases. The illustration of case 1 (HPCS) and case 5 (prolonged bradycardia) were shown.

In conclusion, from the retrospective analysis of 157 adult DHF patients we demonstrated 7 cases presented with unusual severe complications namely 4 HPCS and 3 related disorders. Immune pathogenesis plays a big role in the development of these complications. The treatment in these cases consisted of high dose corticosteroid and high dose intravenous immunoglobulin G. Five cases survived with complete recovery whereas the other two cases died. The first case died from delayed treatment with co-infection. The second case died from intracranial bleeding.

The detail history of each case were presented in Table I, II and the illustration of case 1 was presented in Fig 4-1, 4-2, 4-3 and case 5 in Fig 5

The finding of myocarditis (prolonged bradycardia) in case 5 was quite interesting. The patient reported from Hong Kong in 2010, died from shock and tachycardia. Resuscitation by fluid therapy was given without corticosteroid or IVIg therapy.[69] The literature reviewed from 6154 DHF cases in Thailand found that only 2 cases had myocarditis as manifested by bradycardia and hypotension. Immune pathogenesis could play an important role for this complication. However, corticosteroid therapy and the outcome of the patients were not mentioned.

Table I Group I very severe multiorgan failure in 4 adult DHF

No	Sex Age yrs	Complication detection D*	Clinical Feature								Transfusion Rx	Rx Start on D*			Outcome
			HPCS	Shock	ARDS	Cardiac	CNS	GI	ARF	Bleeding		Dexa	MP	IVIg	
1 Dn2	F 22	D-2	+	+	+	+	++	++	0	++ GI	+	+ D2-8	+ D6	+ D3-7	S
2 Dn2	F 43	D-6	+	+	+	+	0	+	0	+	0	+ D4-9	0	+ D9	S
3 Dn3	F 45	D-2	+	0	+	+	++	++	+	++ DIC	+	+ D6 delay	0	+ D6-7	P
4 * IgM +	M 65	D-3	+	0	0	0	+	++	+	0 DIC	0	+ D3-7	0	+ D7	P

D* = day of illness, HPCS = hemophagocytic syndrome, AFR = acute renal failure,
Dexa = dexamethasone, MP = methyl prednisolone, S = Satisfactory, P = Poor, * died from infection

Table II Group II severe unusual complication in adult DHF

No	Sex Age yrs	Complication detect on D*	Clinical Feature					Transfusion Rx	Rx Start on D*			Outcome	Days Hospitalization
			Shock	Cardiac	CNS	GI	Bleeding		Dexa	MP	IVIg		
5 IgM +	F 48	D-4	0	++	0	++	+	0	+ D4-6	0	+ D7	S	8
6 IgM +	M 40	D-4	+	0	+	++	++	+	+ D4-8	0	0	S	10
7 IgM +	M 16	D-6	0	0	0	++ bleeding	++ DIC	PRC 3 U PC 2 U FFP 3 U Cryo 10 U	+ D6	0	0	S	6

Abbreviation see Group I, Cryo = cryoprecipetate, FFP = fresh frozen plasma, S = Satisfactory

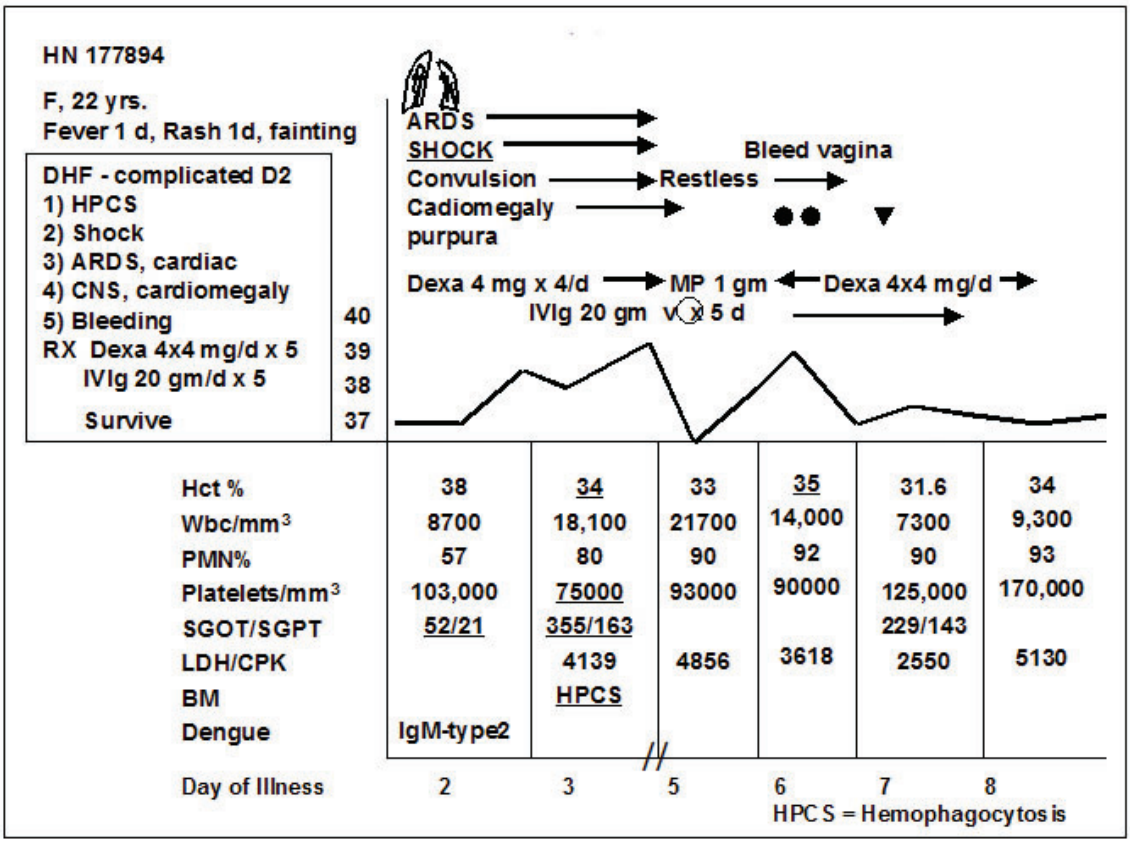

Fig. 4-1 Severe complicated DHF case 1

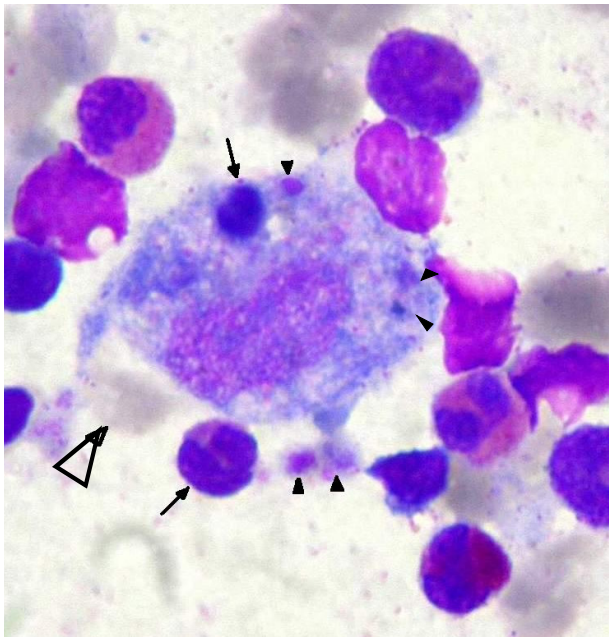

Fig. 4-2 Hemophagocytosis in the bone marrow by mature histiocytes ingested leukocytes (⟶), platelets (▲) and red blood cell (△)

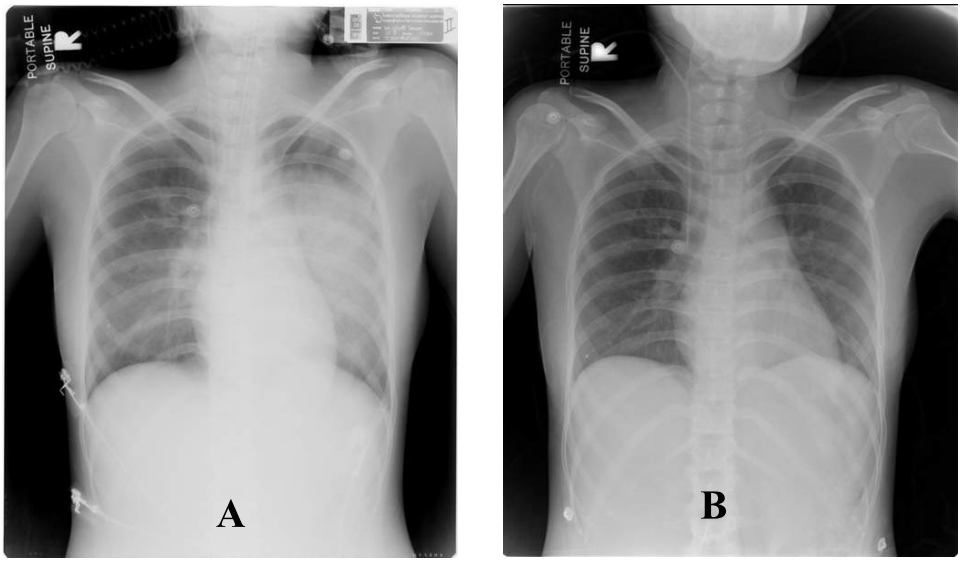

Fig. 4-3 **A:** ARDS on 2nd day of illness; **B:** Full recovery on 6th day of illness

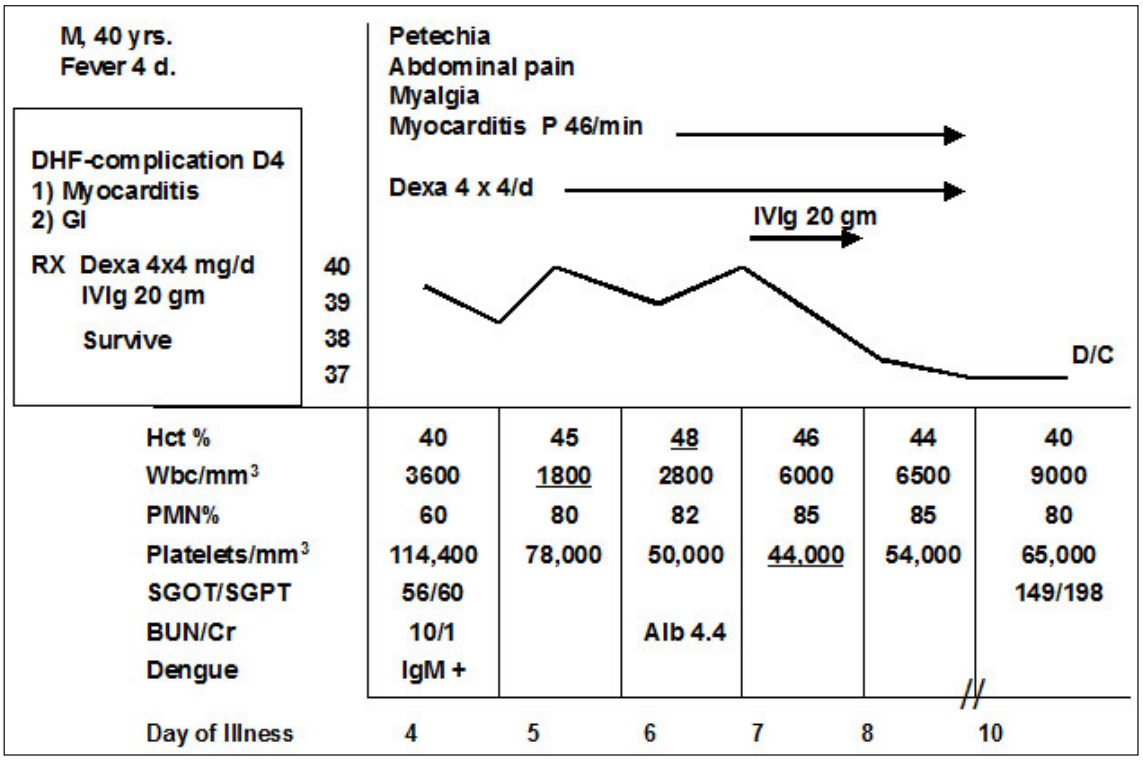

Fig. 5 Severe complicated DHF case 5

References

1. *Nimmannitya S, Halstead SB, Chen SN, Margiotta MR. Dengue and Chikungunya virus infection in man in Thailand 1962-1964. Observation on hospitalized patient with hemorrhagic fever. Am J Trop Med Hyg 1969;518:954-71.*
2. *Gubler DJ. Dengue and dengue hemorrhagic fever. Clini Microbiol Rev 1958;11:480-96.*
3. *Halstead SB, Nimmannitya S, Margiotta MR. 1969 Dengue and chikungunya virus infection in man in Thailand. 1962-1964.*
4. *WHO. 1997. Dengue Hemorrhagic Fever Diagnosis Treatment Prevention and Control. Geneva. WHO.*
5. *Kittiprapan W. Dengue Shock Syndrome in Pediatric Patients at Buddhachinaraj Hospital. Buddhachinaraj Medical Journal 2010;27(1):67-75.*
6. *Sosothikul D, Seksarn P, Pongsewalak S, Thisyakorn U, Lusher J. Activation of endothelial cells, coagulation and fibrinolysis in children with dengue virus infection. Thromb Haemost 2007;97:627-34.*
7. *Avirutnan P, Punyadee N, Noisakran S, Komoltri C, Thiemmeca S, Auethavornanan K, et al. Vascular Leakage in Severe Dengue Virus Infections: A Potential Role for the Nonstructural Viral Protein NS1 and Complement. JID 2006;193:1078-88.*
8. *Shresta S, Sharar KL, Prigozhin DM, Beatty PR, Harris E. Murine Model for Dengue Virus-Induced Lethal Disease with Increased Vascular Permeability. Journal of Virology 2006;80(20):10208-17.*
9. *Mongkolsapaya J, Duangchinda T, Dejnirattisai W, Vasanawathana S, Avirutnan P, Jairungsri A, et al. T Cell Responses in Dengue Hemorrhagic Fever: Are Cross-Reactive T Cells Suboptimal? The Journal of Immunology 2006;176:3821-9.*
10. *Innis BL. Dengue and Dengue Hemorrhagic Fever. Exotic Viral Infections. Edited by J.S. Porterfield. Published in 1995 Chapman & Hall, London;1995:103-46.*
11. *Srichaikul T, Nimmannitya S, Sripaisarn T, Kamolsilpa M. Platelet Function During The Acute Phase of Dengue Hemorrhagic Fever. Southeast Asian J Trop Med Pub Hlth 1989;20(1):19-25.*
12. *Punyagupta S. Dengue Hemorrhagic Fever in Adults, an Emerging Problem in Thailand: a Retrospective Study of 75 Adult Dengue Infection in 2007. J Infect Dis Antimicrob Agents 2009;26(1):1-5.*
13. *Rongrungruang Y, Leelarasamee A. Characteristics and Outcomes of Adult Patients with Symptomatic Dengue Virus Infections. J Infect Dis Antimicrob Agents 2001;18:19-23.*
14. *Wichmann O, Hongsiriwon S, Bowonwatanuwong C, Chotivanich K, Sukthana Y, Pukrittayakamee S. Risk factors and clinical features associatd with severe dengue infection in adults and children during the 2001 epidemic in Chonburi, Thailand. Tropical Medicine and International Health 2004;9(9):1022-9.*
15. *Chan KP, Lau GKF, Doraisingham S, Chan YC. Adult dengue deaths in Singapore. Clinical and Diagnostic Virology 1995;4:213-22.*
16. *Sam SS, Omar SFS, Teoh BT, Abd-Jamil J, AbuBakar S. Review of Dengue Hemorrhagic Fever Fatal Cases Seen Among Adults: A Retrospective Study. PLoS Negl Trop Dis 2013;7(5):e2194.*
17. *Halstead SB. Antibody, Macrophages, Dengue Virus Infection, Shock and Hemorrhage: A Pathogenetic Cascade. Reviews of Infectious Diseases 1989;11(4):s830-9.*
18. *Clyde K, Kyle JL, Harris E. Recent Advances in Deciphering Viral and Host Determinants of Dengue Virus Replication and Pathogenesis. Journal of Virology 2006;80(23):11418-31.*

19. Srichaikul T, Punyagupta S, Kanchanapoom T, Chanokovat C, Likittanasombat K, Leelasiri A. Hemophagocytic Syndrome in Dengue Hemorrhagic Fever with Severe Multiorgan Complications. J Med Assoc Thai 2008;91(1):104-9.
20. ถนอมศรี ศรีชัยกุล, สมพนธ์ บุณยคุปต์, วิเชียร มงคลศรีตระกูล, สุวรรณี จิตตภักดีบดินทร์. Hemophagocytic Syndrome: An Analysis of 7 Cases and the Literatures Review. J Hematol Transfus Med 2004;14(4):263-80.
21. Sorakhunpipitkul L, Punyagupta S, Srichaikul T, Tribuddharat S. Thai Adult Dengue Hemorrhagic Fever During 2008-2010: Seven Cases Presented with Severe Multiorgan Failure and Successfully Treated with High Dose of Corticosteroids and Intravenous Immunoglobulin G. J Infect Dis Antimicrob Agents 2011;28(2):99-103.
22. ลัดดา สรคุณพิพิธกุล, ถนอมศรี ศรีชัยกุล, สิทธิเทพ ธนกิจจารุ, กิตติศักดิ์ เก่งสกุล, ไพบูลย์ ปุญญฤทธิ์. Hemophagocytic Syndrome จาก Epstein Barr Virus ทำให้เกิดระบบทางเดินหายใจล้มเหลวและต่อมน้ำเหลืองโตมาก: รายงานผู้ป่วย 1 รายที่รอดชีวิตจากการรักษาด้วย Acyclovir และ Pulse Methylprednisolone ทางหลอดเลือดดำร่วมกับ Intravenous Immunoglobulin G และทบทวนวรรสาร. J Hematol Transfus Med 2011;21(2):95-101.
23. ถนอมศรี ศรีชัยกุล. Multiorgan Failure in Dengue Hemorrhagic Fever Related to Hemophagocytic Syndrome. J Hematol Transfus Med 2007;17(4):371-6.
24. Pongtanakul B, Narkbunnam N, Veerakul G, Sanpakit K, Viprakasit V,Tanphaichitr VT, et al. Dengue Hemorrhagic Fever in Patients with Thalassemia. J Med Assoc Thai 2005;88(8):s80-5.
25. Veerakul G, Sanpakit K, Tanphaichitr VS, Mahasandana C, Jirarattanasopa N. Secondary hemophagocytic lymphohistiocytosis in children: an analysis of etiology and outcome. J Med Assoc Thai;2002:85(2):s530-41.
26. Ray S, Kundu S, Saha M Chakrabarti P. Hemophagocytic Syndrome in Classic Dengue Fever. J Glob Infect Dis 2011;3(4):399-401.
27. Wong KF, Chan JKC, Chan JCW, Lim WWL, Wong WK. Letter to the Editor: Dengue Virus Infection-Associated Hemophagocytic Syndrome. American J Hematol 1991;38:339-40.
28. Bierman HR and Nelson ER. Hematodepressive virus disease of Thailand. Annals of Internal Medicine 1965;62:867-84.
29. Na-Nakorn S, Suingdumrong A, Pootrakul S, and Bhamarapravati N. Bone marrow studies in Thai hemorrhagic fever. The American Journal of the Medical Sciences 1966;35:54-5.
30. Nelson ER, Bierman HR and Chulajata R. Hematologic findings in the 1960 hemorrhagic fever epidemic (dengue in Thailand). The American Journal of Tropical Medicine and Hygiene 1964;13:642-9.
31. Nelson ER, Bierman HR and Chulajata R. Hematologic phagocytosis in postmortem bone marrow of dengue hemorrhagic fever. The American Journal of the Medical Sciences. 1966;252:68-74.
32. Bhamarapravati N, Tuchinda P. Boonyapakavik V. Pathology of Thailand hemorrhagic fever: a study of 100 autopsy cases. Annals of Tropical Medicine and Parasitology 1967; 61:500-10.
33. Kho LK, Wulur H and Himawan T. Blood and bone marrow in dengue hemorrhagic fever. Paediatrica Indonesiana 1972;12:31-9.
34. Putintseva E, Vega G and Fernandez L. Alteration in thrombopoiesis in patients with thrombocytopenia produced by dengue hemorrhagic fever. Nouvelle Revue Francaise Hematologic 1986;28:269-73.
35. Lin SF, Liu HW, Chang CS, Yen JH, Chen TP. Hematological aspects of dengue fever. Kaohsiung Journal of Medical Sciences 1989;5:12-6.
36. Nakao S, Lai CJ and Young NS. Dengue virus, a flavi virus, propagates in human bone marrow progenitors and hematopoietic cell lines. Blood. 1989;74;1235-40.
37. Murgue B, Cassar O, Guigon M, Chungue E. Dengue virus inhibit human hematopoietic progenitor growth in vitro. Journal of Infectious Disease 1997;175:1497-501.
38. La Russa VF, Putnak JR and Knight RD. Dengue virus infection of stromal cells in Dexter cultures of human marrow (abstract) Experimental Hematology 1991;19:479.
39. La Russa VF, Cutting MA, Kanshal S et al. Generation of stromal cell colonies from CD34+ cells (abstract). Blood 1993;82:98a.
40. Maze R, Sherry B, Kwon Bs, Cerami A and Brox Meyer HE. Myelosuppressive effect in vivo of purified recombinant murine macrophage inflammatory protein-1 alpha. The Journal of Immunology 1992;149:1004-9.
41. Oppenheim J. Zacharie C, Mukuaida N and Matsuskinna K. Properties of the novel proinflammatory supergene 'intercrine' cytokine family. Annual Review of Immunology 1991;9:617-48.
42. Dunlop D, Wright E, Lorimore S. et al. Demonstration of stem cell inhibition and myeloprotective effects of SCI/rh MIP 1a in vivo. Blood 1992;79:2221-5.
43. Williams DE, Devries P, Namen AE, et al. The steel factor. Developmental Biology 1992;151:368-76.
44. Williams DE, and Lyman SD. Characterization of the gene product of the steel locus. Progress in Growth Factor Research 1991;3:235-42.
45. Laur F, Murgue B, Deparis X, Roche C, Cassar O, chungue E. Plasma levels of tumour necrosis factor alpha and transforming growth factor beta-1 in children with dengue – 2 virus infection in French Polynesia. Transection Royal society of Tropical Medicine and Hygiene. 1998;92:654-6.
46. Avirutnan P, Malasit P, seliger B, Bhakdi S, Husmann M. Dengue virus infection of human endothelial cells leads to chemokine production, complement activation and apoptosis. Journal of Immunology 1998;161:6338-46.
47. Raghupathy R, Chaturvedi UC, Al-Sayer H et al. Elevated levels of IL-8 in Dengue Hemorrhagic fever. Journal of Medical Virology 1998;56:280-5.
48. Kurane I, Innis BL, Nimmannitya S and et al. Activation of T lymphocytes in dengue virus infections. High levels of soluble interleukin 2 receptor, soluble CD8, interleukin 2, and interferon - γ in sera of children with dengue. The Journal of Clinical Investigation. 1991;88:1473-80.
49. Kurane I, Innis BL, Nimmannitys S, Nisalak A, Meager A and Ennis FA. High levels of interferon alpha in the sera of children

with dengue virus infection. The American Journal of Tropical Medicine and Hygiene 1993;48:222-9.

50. *Hober D, Poli L, Roblin B et al. Serum levels of tumour necrosis factor - α (TNF-2), interleukin 6 (IL-6) and interleukin – 1β (IL-1β) in dengue infected patients. The American Journal of Tropical Medicine and Hygiene 1993;48:324-31.*
51. *Yadar M, Kamath KR, Iyngkaran N and Sinniah M. Dengue Hemorrhagic fever and dengue shock syndrome : are they tumour necrosis factor – mediated disorders? Federation of European Medical Sciences of Microbiology and Immunology (Netherland) 1991;89:45-50.*
52. *Srichaikul T. Haematology in dengue and dengue haemorrhagic fever. Bailliere's Clinical Haematology 2000;13(2):1-16.*
53. *Srichaikul T, Punyagupta S, Nitiyanant P, Alkarawong K. Disseminated intravascular coagulation in adult dengue haemorrhagic fever: Report of three cases. Southeast Asian J Trop Med Pub Hlth 1975;6(1):106-14.*
54. *Srichaikul T. Disseminated intravascular coagulation in dengue haemorrhagic fever. Southeast Asian J Trop Med Pub Hlth 1987;18(3):303-11.*
55. *Tavodova M. Dengue Fever. South Sudan Medical Journal 2012;5(1):13-6.*
56. *Srichaikul T, Nimmanitaya S, Artchararit N, Siriasawakul T, Sungpeuk P. Fibrinogen metabolism and disseminated intravascular coagulation in dengue hemorrhagic fever. American J Trop Med & Hygiene 1977;26(3):525-32.*
57. *Chuansumrit A, Teeraratkul S, Wanichkul S, Treepongkaruna S, Sirachainan N, Pakakasama S, et al. Recombinant-activated factor VII for control and prevention of hemorrhage in nonhemophilic pediatric patients. Blood Coagulation and Fibrinolysis 2010;21(4):354-62.*
58. *Mairuhu ATA, Gillavry MRM, Setiati TE, Soemantri A, Cate HT, Brandjes DPM, Gorp ECMV. Is clinical outcome of dengue-virus infections influenced by coagulation and fibrinolysis? A critical review of the evidence. The Lancet Infectious Diseases 2003;3:33-41.*
59. *Kalayanarooj S, Uthaisang E, Nimmannitya S. A study on coagulation and fibrinolytic system changes in dengue hemorrhagic fever patients. Studies/Collaborative Studies on Dengue infections/ Dengue Hemorrhagic Fever:312-4.*
60. *Srichaikul T. Pathogenesis of Bleeding in DHF: Role of Platelet and Coagulation Abnormalities. J Med Assoc Thai 1989;72(4):239-42.*
61. *Krishnamurti C, Kalayanarooj S, Cutting MA, Peat RA, Rothwell SW, Reid TJ, et al. Mechanisms of Hemorrhage in dengue without circulatory collapse. Am J Trop Med Hyg 2001;65(6):840-7.*
62. *Mitrakul C, Poshyachinda M, Futrakul P, Sangkawibhan, Ahandrik S. Hemostatic and platelet kinetic studies in dengue hemorrhagic fever. Am J Trop Med & Hygiene 1977;26(5):975-84.*
63. *Phanichyakarn P, Israngkura P, Krisarin C, Pongpanich B, Dhanamitta S, Valyasevi A. Studies on dengue haemorrhagic fever IV. Fluorescent staining of the immune complexes on platelets. Journal Medical Association of Thailand 1977;60:307-11.*
64. *Boonpucknavig S, Vuttiviroj O, Bunnag C, Bhamarapravati N Nimmannitya S. Demonstration of dengue antibody complexes on the surface of platelets from patients with dengue hemorrhagic fever. American Journal of Tropical Medicine and Hygiene 1979;28:881-4.*
65. *Wang S, HeR, Patarapotikul J, Innis BL, Anderson R. Antibody enhanced binding of dengue – 2 virus to human platelets. Virology 1995;213:254-7.*
66. *Bokisch VA, Top FH, Russell PK, Dixon F, Muller-Eberhard J. The potential pathogeneic role of complement in dengue hemorrhagic shock syndrome. The New England Journal of Medicine 1973;289:996-1000.*
67. *Prasad KPR, Alahakoon DGS, Gunawardane JN. Effect of prednisolone during defervescence in dengue haemorrhagic fever: an open label controlled study. Galle Medical Journal 2008;13(1):19-21.*
68. *Srichaikul T, Punyagupta S, Sorakhunpipitkul L, Udomsubpayakul U. Adjunctive Corticosteroid Therapy in 149 Grade II (Non-Shock) Adult DHF Patients: An Analysis during January 2008-February 2010. J Med Assoc Thai 2011;94(12):1419-23.*
69. *Goh PL. Dengue perimyocarditis: a case report. Hong Kong J of Emerg Med 2010;17(1):58-60.*